



# Evaluation of Maxillary Sinus Pathology, Concha Bullosa and Ostium Obstruction in Cleft Lip and Palate Using Cone-beam Computed Tomography

## Dudak ve Damak Yarığında Maksiller Sinüs Patolojisi, Konka Bülloza ve Ostium Tıkanıklığının Konik Işınlı Bilgisayarlı Tomografi Kullanılarak Değerlendirilmesi

Hazal DUYAN YÜKSEL<sup>1</sup>, Berkhas TUMANI ÜSTDAL<sup>2</sup>, Burcu EVLİCE<sup>1</sup>

<sup>1</sup>Çukurova University Faculty of Dentistry, Department of Oral and Maxillofacial Radiology, Adana, Türkiye

<sup>2</sup>Fatma Kemal Timuçin Oral and Dental Health Care Hospital, Clinic of Oral and Maxillofacial Radiology, Adana, Türkiye

### ABSTRACT

**Objective:** Cleft lip and palate (CLP) is one of the most common congenital anomalies in the craniofacial region. Many malformations involving the midface may occur in patients with CLP. This study aimed to evaluate the effect of a cleft on maxillary sinus pathology (MSP), concha bullosa and ostium obstruction using cone beam computed tomography (CBCT).

**Methods:** A total of 90 patients out of which 30 were categorized as unilateral CLP (UCLP), 30 were categorized as bilateral CLP and 30 were categorized as control, were included in this retrospective study. The effects of cleft presence to MSP, concha bullosa and ostium obstruction were determined using CBCT images.

**Results:** A total of 180 right and left sides of the study population were divided into two groups as 90 cleft and 90 normal sides. There was no statistically significant relationship between the presence of cleft and the parameters examined in UCLP patients. For all patients, in the presence of a cleft, the incidences of MSP (83.3%,  $p<0.001$ ) and ostium obstruction (17.8%,  $p=0.011$ ) were statistically significant. However, the presence of a cleft did not have a statistically significant effect on the concha bullosa. The presence of a cleft increased MSP 4.2 times and ostium obstruction 3.7 times.

### ÖZ

**Amaç:** Dudak ve damak yarığı (DDY), kraniyofasiyal bölgede en sık görülen konjenital anomalilerden biridir. DDY'li hastalarda orta yüzü ilgilendiren birçok malformasyon ortaya çıkabilir. Bu çalışmada, yarıkların maksiller sinüs patolojisi (MSP), konka bülloza ve ostium tıkanıklığı üzerine etkisinin konik ışınlı bilgisayarlı tomografi (KIBT) kullanılarak değerlendirilmesi amaçlandı.

**Yöntemler:** Bu retrospektif çalışmaya 30'u unilateral DDY (UDDY), 30'u bilateral DDY ve 30'u kontrol olmak üzere toplam 90 hasta dahil edildi. Yarık varlığının MSP, konka bülloza ve ostium tıkanıklığına etkisi KIBT görüntüleri kullanılarak belirlendi.

**Bulgular:** Çalışma popülasyonunun toplam 180 sağ ve sol tarafı 90 yarık ve 90 normal taraf olmak üzere iki gruba ayrıldı. UDDY hastalarında yarık varlığı ile incelenen parametreler arasında istatistiksel olarak anlamlı bir ilişki bulunamadı. Tüm hastalarda yarık varlığında MSP (%83,3,  $p<0,001$ ) ve ostium tıkanıklığı (%17,8,  $p=0,011$ ) görülme sıklığı istatistiksel olarak anlamlıydı. Ancak yarık varlığının konka bülloza üzerinde istatistiksel olarak anlamlı bir etkisi olmadı. Yarık varlığı MSP'yi 4,2 kat, ostium tıkanıklığını ise 3,7 kat artırdı.

**Address for Correspondence:** Hazal Duyan Yüksel, Çukurova University Faculty of Dentistry, Department of Oral and Maxillofacial Radiology, Adana, Türkiye

**E-mail:** hazalduyan@hotmail.com **ORCID ID:** orcid.org/0000-0002-2765-0631

**Cite this article as:** Duyan Yüksel H, Tumanı Üstdal B, Evlice B. Evaluation of maxillary sinus pathology, concha bullosa and ostium obstruction in cleft lip and palate using cone-beam computed tomography. Bezmialem Science. 2025;13(2):117-22

**Received:** 20.05.2024

**Accepted:** 10.12.2024

**Published date:** 24.04.2025



**ABSTRACT**

**Conclusion:** While the presence of a cleft increased the risk of MSP and ostium obstruction, it was not associated with the presence of a concha bullosa.

**Keywords:** Cleft lip and palate, concha bullosa, cone beam computed tomography, maxillary sinus, ostium

**ÖZ**

**Sonuç:** Yarık varlığı MSP ve ostium tıkanıklığı riskini artırırken konka bülloza varlığı ile ilişkili değildi.

**Anahtar Kelimeler:** Dudak ve damak yarığı, konka bülloza, konik ışınli bilgisayarlı tomografi, maksiller sinüs, ostium

**Introduction**

Cleft lip and palate (CLP), one of the most common congenital anomalies in the maxillofacial area (1,2) is caused by the fusion disorder of the primary palate at the beginning of the fetal period (3). Patients with CLP experience many problems related to hearing, speech, nutrition, dentition, upper respiratory tract and facial morphology. Since the maxillary sinus is one of the main structures of the mid-face, it is an expected result that the maxillary sinuses are morphologically affected (3,4). Also, unilateral CLP (UCLP) can affect the external facial soft tissues, dental arches, maxilla, and morphology of the nasal airways (5-7).

The etiology of sinusitis in patients with CLP is not entirely understood. Factors such as external nasal deformity, rhinosinusitis, nasal concha variations and septum deviation are common in these patients (8,9). These factors can cause airway resistance, mouth breathing and consequently maxillary sinusitis (10). Patients with UCLP have a characteristic nasal deformity characterized by structural asymmetry and bending of the septum. It is important for practitioners to understand the anatomy of the maxillary sinuses, especially in patients with UCLP who may exist the above-mentioned disorders.

There are previous studies in the literature investigating the pathologies and variations related to the maxillary sinus and nasal cavity region in patients with CLP (8,9,11-15), but additional information is needed regarding these regions in patients with CLP. The objective of this study is to investigate the relationship between the presence of a cleft, maxillary sinus pathology (MSP), concha bullosa, and, unlike previous studies, ostium obstruction using cone beam computed tomography (CBCT) images.

**Methods****Study Population**

This study was approved with the number: 145, date: 14.06.2024 by the Çukurova University's Non-Invasive Clinical Research Ethics Committee, and was prepared in accordance with the Declaration of Helsinki, revised in 2013. CBCT images of UCLP, bilateral CLP (BCLP) and control patients were included in this retrospective, observational and case-control study. Firstly, since the number of BCLP patients was minimal, 15 male and 15 female BCLP patients were randomly selected from the patient archive. UCLP and control groups were then sorted by gender and matched similarly in terms of age ( $\pm 1$ ). If a patient had more than one match of the same gender and age, a random

selection was made among them. Randomization was performed using the random module in the Python programming language. Random selection was based on achieving unbiased and balanced representation of gender and age across the BCLP, UCLP, and control groups, minimizing selection bias. The CBCT scans of the patients with CLP were routinely obtained for postoperative evaluation of the repaired clefts at least nine months after the last operation. CBCT images of the control group were available in the archive of dentomaxillofacial radiology department and they were performed for different dental indications. As low as diagnostically acceptable being indication-oriented and patient-specific (ALADAIP) principle and the current European SEDENTEX CT guidelines were considered to perform the CBCTs. All patients or their parents applying to the related department filled out an informed consent form as a standard procedure because it could be used in scientific studies. The exclusion criteria were following: Inflammatory maxillary sinus diseases excluding mucositis and sinusitis, craniofacial syndrome, craniofacial pathologies, trauma or skeletal/dental surgery history and bone dysplasias. The desired results from the study were to determine the distribution and effect of cleft presence related to MSP, concha bullosa and ostium obstruction.

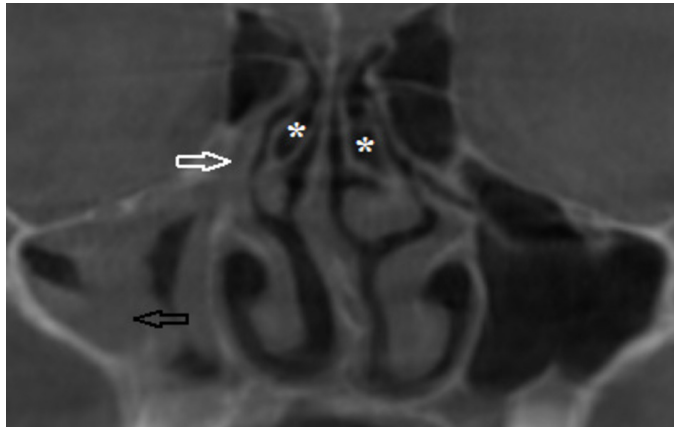
**Imaging Procedure**

Radiological assessments were analyzed by two maxillofacial radiologists (HDY and BTÜ). All CBCT images were acquired by a Planmeca Promax® 3D Mid (Helsinki, Finland) device in standard resolution mode (90 Kv, 10 mA, 27 s). DICOM format data were transferred to Planmeca Romexis 3.8.1.R software (Helsinki, Finland) and all images were evaluated in coronal, axial and sagittal sections. Any mucosal thickening (MT) more than two mm in the maxillary sinus was considered as "pathological". MSP, concha bullosa, and ostium obstruction were recorded as "present/absent" (Figure 1). All of the radiological assessments were evaluated independently by two observers at two-week intervals. One concha bullosa and one ostium obstruction evaluation differed among the observers, and as a result, a consensus was reached after discussion.

**Statistical Analysis**

For this study, based on an effect size of 0.3 (Cohen's w), a significance level of 0.05, and a power of 0.95, the required sample size was determined to be 144. Considering a potential 25% data loss, the final sample size was increased to 180. This calculation was performed using the G\*Power 3.1 software. The examined parameters were shown in tables as frequency and percentage. Chi-square test was performed to determine

relationships between defined categorical variables, and Odds ratios were calculated to determine the effect of presence of cleft on different variables. Whether there was a difference between the cleft and non-cleft sides of UCLP patients in terms of the parameters examined was evaluated with the McNemar test. IBM SPSS 20.0 software (Armonk, NY) was used for statistical analysis ( $p < 0.05$ ).



**Figure 1.** Parameters examined on cone beam computed tomography image  
*Black arrow: Maxillary sinus pathology, \*: Concha bullosa, White arrow: Ostium obstruction*

## Results

A total of 180 sides of 90 patients (45 female, 45 male) including 30 UCLP patients [mean age:  $12.9 \pm 1.8$ ; minimum (min.): 8, maximum (max.): 15], 30 BCLP patients (mean age:  $12.8 \pm 1.6$ ; min.: 8, max.: 15) and 30 controls (mean age:  $12.8 \pm 1.8$ ; min.: 8, max.: 15) were examined. The groups were categorized as; presence of cleft (30 cleft sides of 30 UCLP patients and 60 cleft sides of 30 BCLP patients) and absence of cleft (30 normal sides of 30 UCLP patients and 60 normal sides of 30 control patients). For all patients, in the presence of a cleft, the prevalence of the MSP (83.3%) and ostium obstruction (17.8%) were statistically significantly higher compared to the absence of a cleft (54.4% and 5.6%, respectively). The presence of a cleft increased MSP 4.2 times and ostium obstruction 3.7 times. There was no statistically significant relationship between the presence of a cleft and the concha bullosa (Table 1).

There was no significant difference in the parameters examined in the cleft and non-cleft sides of UCLP patients (Table 2).

## Discussion

Computed tomography (CT) is considered the gold standard for imaging paranasal sinuses (16,17). However, CBCT has a lower radiation dose, higher resolution, and shorter scan time compared to CT (18-20). It is also a reliable and accurate tool in

**Table 1.** Distribution of the cleft according to the parameters examined in all patients

	Presence of cleft (n=90)	Absence of cleft (n=90)	Total (n=180)	p-value	Odds ratio (CI)
MSP	75 (83.3)	49 (54.4)	124 (68.9)	<0.001*	4.2 (2.1-8.4)
CB	63 (70)	56 (62.2)	119 (66.1)	0.270	1.4 (0.8-2.6)
OO	16 (17.8)	5 (5.6)	21 (11.7)	0.011*	3.7 (1.3-10.5)

MSP: Maxillary sinus pathology, CI: Confidence interval, \* $p < 0.05$

**Table 2.** Distribution of parameters examined in cleft and non-cleft sides of UCLP patients

		MSP-cleft side			p-value
		Absence	Presence	Total	
MSP	Absence	3 (37.5)	5 (62.5)	8 (100)	0.727
Non-cleft side	Presence	3 (13.6)	19 (86.4)	22 (100)	
	Total	6 (20)	24 (80)	30 (100)	
		CB-cleft side			p-value
		Absence	Presence	Total	
CB	Absence	3 (33.3)	6 (66.7)	9 (100)	0.754
Non-cleft side	Presence	4 (19)	17 (81)	21 (100)	
	Total	7 (23.3)	23 (76.7)	30 (100)	
		OO-cleft side			p-value
		Absence	Presence	Total	
OO	Absence	23 (85.2)	4 (14.8)	27 (100)	0.687
Non-cleft side	Presence	2 (66.7)	1 (33.3)	3 (100)	
	Total	25 (83.3)	5 (16.7)	30 (100)	

UCLP: Unilateral cleft lip and palat

determining the relationship between anatomical structures and adjacent tissues in the maxillofacial region (21). The aim of this current study was to evaluate the possible relationship between MSP, concha bullosa and ostium obstruction with the presence of a cleft using CBCT.

In certain pediatric patients where conventional X-ray techniques fail to provide a definitive diagnosis, it may be essential to employ an advanced imaging modality like CBCT. Children are more vulnerable to ionizing radiation risks due to the rapid growth of their tissues (22). CBCT imaging must be conducted adhering to the ALADAIP principle and should be employed when the benefit to pediatric patients outweighs the potential risks. In this research, none of the CBCT referrals were specifically related to the study. The CBCTs of the study population were already available in the archive of dentomaxillofacial radiology department.

When the literature was examined, Citron et al. (11), Kula et al. (12) and Pacnahad et al. (13) reported higher MT in the maxillary sinuses of CLP patients compared to control groups. 180 sides of 90 patients were evaluated in the current study. As a result, two groups of 90 cleft and 90 non-cleft sides were performed. The prevalence of MSP (83.3%) in the presence of a cleft was statistically significantly higher than absence of a cleft (54.4%). Suzuki et al. (8) reported that 32.0% of CLP patients and 21.0% of all sides had a minimum 10.0% soft tissue density shadow at least one of the maxillary sinuses. Ishikawa et al. (9) evaluated patients with CLP, and reported that there was no difference between the cleft groups and control group in terms of rhinosinusitis. Cagici et al. (23) determined that the thickening amount should be a minimum of 2 mm in order to detect sinus MT. In addition, they accepted the thickness above this border as pathological thickening. In present study, the amount of pathological MT was accepted as 2 mm and above. There were studies reporting the prevalence of maxillary sinus MT as 12%, 46.2% and 60.5% (16,24,25). Similar to these prevalences, the prevalence of MSP in the absence of cleft was 54.4% in the current study. In the presence of a cleft, this rate (83.3%) was significantly higher than the absence of a cleft and cleft presence increased the risk of MSP 4.2 times. In addition, there was no significant difference in the prevalence of MSP between the cleft and non-cleft sides in UCLP patients similar to Citron et al. (11) and Kula et al. (12) findings. In the study of Suzuki et al. (8) unlike these results, sinusitis was more severe on the non-cleft side than the cleft side.

Concha bullosa is generally asymptomatic; but may be symptomatic depending on the infection, size, drainage or ventilation failure (26). There were studies that reported the prevalence of concha bullosa as 41.7%, 53.7% and 67.5% in the normal population (25-27). Similar to these prevalences, the prevalence of concha bullosa in the absence of a cleft was 62.2% in the current study. Although the prevalence of concha bullosa was higher in the presence of cleft, there was no statistically significant relationship between the presence of cleft and the prevalence of concha bullosa. In parallel with these results, in Dedeoglu et al.'s (14) and Göksel and Özcan's (15) study, there

was no significant difference in the prevalence of concha bullosa in the CLP and control groups.

In the present study, the effect of cleft presence on ostium obstruction was investigated, independent of volume and positioning. It is known that patients with osteomeatal complex obstruction are more prone to sinus diseases (28). The maxillary sinus ostium is located in the posterior superior part of the medial wall and opens into the middle meatus via the ethmoid infundibulum and flows into its posterior part (29). Therefore, any obstruction in the ostium can disrupt the ventilation of the maxillary sinus by interrupting drainage and therefore pathological areas may be accumulated in the maxillary sinus. In the present study, it was observed that the prevalence of obstructed ostium was significantly higher in the presence of a cleft (17.8%) compared to the absence of a cleft (5.6%), and the presence of a cleft increased ostium obstruction by 3.7 times. Although the prevalence of ostium obstruction on the cleft side was higher in patients with UCLP than on the non-cleft side, there was no statistically significant difference. Best of our knowledge, it was the first study to evaluate ostium obstruction in patients with CLP. In the future, more comprehensive studies are needed to examine the relationships between ostium obstruction and ostium location, maxillary sinus volume, and MSP in CLP patients. Further studies can be planned to determine the risk factors of pathologies, especially in the paranasal regions.

### Study Limitations

The most important limitation of this study was that patients were selected by ignoring that viral or allergic infections might increase in certain seasons. Another limitation was that, due to the retrospective nature of this study, it was not possible to perform a clinical evaluation of the patients' paranasal sinuses or osteomeatal complex, nor to determine whether the incidence of sinusitis was associated with various interventions applied for CLP treatment. In addition, the different findings in the studies must be considered with the understanding that they may result from different definitions of both MSP and ostium obstruction during the methodological design (8,11-13,30).

### Conclusion

The results of the present study showed that although the prevalence of MSP, concha bullosa and ostium obstruction on the cleft side was higher in patients with UCLP, there was no statistically significant difference between the cleft and non-cleft sides (Table 2). When all groups were evaluated (Table 1), it was found that the presence of a cleft increased the presence of MSP 4.2 times and ostium obstruction 3.7 times. As a result; within limitations, it has been shown that the presence of a cleft can be a risk factor for MSP and ostium obstruction.

### Ethics

**Ethics Committee Approval:** This study was approved with the number: 145, date: 14.06.2024 by the Çukurova University's Non-invasive Clinical Research Ethics Committee, and was prepared in accordance with the Declaration of Helsinki, revised in 2013.



**Informed Consent:** All patients or their parents applying to the related department filled out an informed consent form as a standard procedure because it could be used in scientific studies.

#### Footnotes

#### Authorship Contributions

Concept: H.D.Y., B.T.Ü., B.E., Design: H.D.Y., B.E., Data Collection or Processing: H.D.Y., B.T.Ü., Analysis or Interpretation: H.D.Y., B.E., Literature Search: H.D.Y., B.T.Ü., Writing: H.D.Y., B.T.Ü., B.E.

**Conflict of Interest:** No conflict of interest was declared by the authors.

**Financial Disclosure:** The authors declared that this study received no financial support.

#### References

1. Celikoglu M, Halicioglu K, Buyuk SK, Sekerci AE, Ucar FI. Condylar and ramal vertical asymmetry in adolescent patients with cleft lip and palate evaluated with cone-beam computed tomography. *Am J Orthod Dentofacial Orthop.* 2013;144:691-7.
2. Shapira Y, Lubit E, Kuftinec MM, Borell G. The distribution of clefts of the primary and secondary palates by sex, type, and location. *Angle Orthod.* 1999;69:523-8.
3. Lawson W, Patel ZM, Lin FY. The development and pathologic processes that influence maxillary sinus pneumatization. *Anat Rec (Hoboken).* 2008;291:1554-63.
4. Lund VJ, Kennedy DW. Staging for rhinosinusitis. *Otolaryngol Head Neck Surg.* 1997;117:35-40.
5. Kyrkanides S, Bellohusen R, Subtelny JD. Skeletal asymmetries of the nasomaxillary complex in noncleft and postsurgical unilateral cleft lip and palate individuals. *Cleft Palate Craniofac J.* 1995;32:428-33.
6. Suri S, Utreja A, Khandelwal N, Mago SK. Craniofacial computerized tomography analysis of the midface of patients with repaired complete unilateral cleft lip and palate. *Am J Orthod Dentofacial Orthop.* 2008;134:418-29.
7. Agarwal R. Anthropometric evaluation of complete unilateral cleft lip nose with cone beam CT in early childhood. *J Plast Reconstr Aesthet Surg.* 2011;64:181-2.
8. Suzuki H, Yamaguchi T, Furukawa M. Rhinologic computed tomographic evaluation in patients with cleft lip and palate. *Arch Otolaryngol Head Neck Surg.* 1999;125:1000-4.
9. Ishikawa Y, Kawano M, Honjo I, Amitani R. The cause of nasal sinusitis in patients with cleft palate. *Arch Otolaryngol Head Neck Surg.* 1989;115:442-6.
10. Turvey TA, Hall DJ, Warren DW. Alterations in nasal airway resistance following superior repositioning of the maxilla. *Am J Orthod.* 1984;85:109-14.
11. Citron I, Lee C, Calabrese CE, Padwa BL. Schneiderian membrane thickness is increased in patients with cleft lip and palate. *Cleft Palate Craniofac J.* 2020;57:296-301.
12. Kula K, Hale LN, Ghoneima A, Tholpady S, Starbuck JM. Cone-Beam computed tomography analysis of mucosal thickening in unilateral cleft lip and palate maxillary sinuses. *Cleft Palate Craniofac J.* 2016;53:640-8.
13. Paknahad M, Pourzal A, Mahjoori-Ghasrodashti M, Khojastepour L. Evaluation of maxillary sinus characteristics in patients with cleft lip and palate using cone beam computed tomography. *Cleft Palate Craniofac J.* 2022;59:589-94.
14. Dedeoglu N, Altun O, Kucuk EB, Altindis S, Hatunogl E. Evaluation of the anatomical variation in the nasal cavity and paranasal sinuses of patients with cleft lip and palate using cone beam computed tomography. *Bratisl Lek Listy.* 2016;117:691-6.
15. Göksel S, Özcan İ. A CBCT study for anatomic variations of osteomeatal complex in patients with cleft lip and palate. *Cleft Palate Craniofac J.* 2023;60:13-20.
16. Shanbhag S, Karnik P, Shirke P, Shanbhag V. Association between periapical lesions and maxillary sinus mucosal thickening: a retrospective cone-beam computed tomographic study. *J Endod.* 2013;39:853-7.
17. Maestre-Ferrín L, Galán-Gil S, Carrillo-García C, Peñarrocha-Diago M. Radiographic findings in the maxillary sinus: comparison of panoramic radiography with computed tomography. *Int J Oral Maxillofac Implants.* 2011;26:341-6.
18. Lu Y, Liu Z, Zhang L, Zhou X, Zheng Q, Duan X, et al. Associations between maxillary sinus mucosal thickening and apical periodontitis using cone-beam computed tomography scanning: a retrospective study. *J Endod.* 2012;38:1069-74.
19. Holberg C, Steinhäuser S, Geis B, Rudzki-Janson I. Cone-beam computed tomography in orthodontics: benefits and limitations. *J Orofac Orthop.* 2005;66:434-44.
20. Aps JK. Cone beam computed tomography in paediatric dentistry: overview of recent literature. *Eur Arch Paediatr Dent.* 2013;14:131-40.
21. İlgüy M, Dölekoğlu S, Fişekçioğlu E, Ersan N, İlgüy D. Evaluation of pneumatization in the articular eminence and roof of the glenoid fossa with cone-beam computed tomography. *Balkan Med J.* 2015;32:64-8.
22. Ludlow JB, Ivanovic M. Comparative dosimetry of dental CBCT devices and 64-slice CT for oral and maxillofacial radiology. *Oral Surg Oral Med Oral Pathol Oral Radiol Endod.* 2008;106:106-14.
23. Cagici CA, Yilmazer C, Hurcan C, Ozer C, Ozer F. Appropriate interslice gap for screening coronal paranasal sinus tomography for mucosal thickening. *Eur Arch Otorhinolaryngol.* 2009;266:519-25.
24. Vallo J, Suominen-Taipale L, Huumonen S, Soikkonen K, Norblad A. Prevalence of mucosal abnormalities of the maxillary sinus and their relationship to dental disease in panoramic radiography: results from the Health 2000 Health Examination Survey. *Oral Surg Oral Med Oral Pathol Oral Radiol Endod.* 2010;109:80-7.
25. Tassoker M. What are the risk factors for maxillary sinus pathologies? A CBCT study. *Oral Radiol.* 2020;36:80-4.
26. Koo SK, Kim JD, Moon JS, Jung SH, Lee SH. The incidence of concha bullosa, unusual anatomic variation and its relationship to nasal septal deviation: A retrospective radiologic study. *Auris Nasus Larynx.* 2017;44:561-70.

27. Smith KD, Edwards PC, Saini TS, Norton NS. The prevalence of concha bullosa and nasal septal deviation and their relationship to maxillary sinusitis by volumetric tomography. *Int J Dent.* 2010;2010:404982.
28. Bolger WE, Butzin CA, Parsons DS. Paranasal sinus bony anatomic variations and mucosal abnormalities: CT analysis for endoscopic sinus surgery. *Laryngoscope.* 1991;101:56-64.
29. Zinreich SJ, Mattox DE, Kennedy DW, Chisholm HL, Diffley DM, Rosenbaum AE. Concha bullosa: CT evaluation. *J Comput Assist Tomogr.* 1988;12:778-84.
30. Kato S, Omori Y, Kanayama M, Hirota A, Ferri M, Apaza Alccayhuaman KA, et al. Sinus mucosa thickness changes and ostium involvement after maxillary sinus floor elevation in sinus with septa. A Cone Beam Computed Tomography Study. *Dent J (Basel).* 2021;9:82.