



Straight Proximal Femoral Nails Mismatch with the Anterior Bowing of the Femur

Düz Proksimal Femur Çivileri Femurun Anterior Eğimi ile Uyumsuzdur

İD Fatih YILDIZ¹, İD Yunus GÜZEL², İD Tunay ERDEN¹, İD Deniz KARA¹, İD Nuh Memet ELMADAĞ¹

¹Bezmialem Vakıf University Faculty of Medicine, Department of Orthopedics and Traumatology, İstanbul, Turkey

²Ordu University Faculty of Medicine, Department of Orthopedics and Traumatology, Ordu, Turkey

ABSTRACT

Objective: Increased anterior bow of the femur due to advanced age and osteoporosis impinges with the distal part of the non-anatomic, standard proximal femoral nails (PFN), which is one of the most preferred implant for the fixation of trochanteric fractures (TF) in the elderly. The relation between increased femoral bowing and standard PFN application was investigated.

Methods: Radiographs of 111 patients (59 men, 52 women; mean age 74.5 years), who were treated with PFN due to TF between 2011 and 2015, were evaluated retrospectively. Relation between the nail and the anterior cortex was determined by measuring the angle between distal anatomical axes of the nail and the femur (ADA). The patients were divided into two groups according to their ADA (group 1 ADA $\leq 4^\circ$ and group 2 ADA $> 4^\circ$). Functional results and pain was evaluated using Harris Hip Score (HHS) and visual analog scale (VAS). Complications were also recorded.

Results: The mean amount of ADA was $4.5^\circ \pm 1.5^\circ$. Forty-seven patients were classified in group 1 and 64 patients were in group 2. The mean HHSs were 80.6 and 79.3 ($p=0.464$), and the mean VAS scores were 2.13 and 5.35 ($p<0.001$) in group 1 and 2, respectively. Five patients were revised due to cut-out of the lag screws (total hip arthroplasty in two patients and revision of the nails in three patients). Union was achieved in all patients without infection.

Conclusion: Because straight femoral nails impinges anterior cortex of the femur with increased bowing, new design PFN with anterior curve is needed especially for shorter or osteoporotic people, or Caucasian population.

Keywords: Femur, trochanteric fracture, proximal femoral nail, anterior bowing

ÖZ

Amaç: Yaşlıların trokanterik kırıklarının (TF) tespitinde sıklıkla tercih edilen anatomik olmayan, düz, standart proksimal femur çivilerinin (PFN) distal ucu, ileri yaş ve osteoporoz nedeniyle eğimi artmış femurun anterior korteksi ile sıkışmaktadır. Bu çalışmada standart PFN uygulaması ile artmış femoral eğim arasındaki ilişki araştırılmıştır.

Yöntemler: 2011 ile 2015 yılları arasında TF nedeniyle PFN uygulanmış olan 111 hasta (59 erkek, 52 kadın; ortalama yaş 74,5) geriye dönük incelendi. Anterior korteks ve çivi arasındaki ilişki, çivi ve femurun distal anatomik aksları arasındaki açının (ADA) ölçümü ile değerlendirildi. Hastalar ADA açılarına göre iki gruba ayrıldı (grup 1 ADA $\leq 4^\circ$ ve grup 2 ADA $> 4^\circ$). Fonksiyonel sonuçlar ve ağrı Harris Kalça Skoru (HHS) ve görsel analog skala (VAS) ile değerlendirildi. Komplikasyonlar kaydedildi.

Bulgular: Ortalama ADA $4.5^\circ \pm 1.5^\circ$ olarak bulundu. Grup 1'de 47 ve grup 2'de 64 hasta mevcuttu. Grup 1 ve grup 2'de ortalama HHS sırasıyla 80,6 ve 79,3 ($p=0,464$) ve ortalama VAS skoru 2,13 ve 5,35 ($p<0,001$) olarak bulundu. Beş hasta lag vidasının sıyrılması nedeni ile revize edildi (iki hasta toplam kalça artroplastisi ile ve üç hasta çivi revizyonu ile). Tüm hastalarda enfeksiyon olmadan kaynama elde edildi.

Sonuç: Femurdaki artmış eğimin, düz çivilerin anterior kortekste sıkışmasına neden olması nedeniyle özellikle Kafkas toplumlarındaki gibi göreceli olarak kısa boylu insanlarda ya da ileri osteoporotik olanlarda anterior eğimli yeni dizayn çivilere ihtiyaç duyulmaktadır.

Anahtar Sözcükler: Femur, trokanterik kırık, proksimal femur çivisi, anterior eğim

Address for Correspondence/Yazışma Adresi: Fatih YILDIZ, Bezmialem Vakıf University Faculty of Medicine, Department of Orthopedics and Traumatology, İstanbul, Turkey
E-mail: yildizfatih@hotmail.com ORCID ID: orcid.org/0000-0003-4475-5379

Received/Geliş Tarihi: 15.11.2017
Accepted/Kabul Tarihi: 26.02.2018

Cite this article as: Yıldız F, Güzel Y, Erden T, Kara D, Elmadağ NM. Straight Proximal Femoral Nails Mismatch with the Anterior Bowing of the Femur. Bezmialem Science 2019;7(1):38-42.

©Copyright 2019 by the Bezmialem Vakıf University
Bezmialem Science published by Galenos Publishing House.

Introduction

In the treatment of trochanteric fractures (TF), stable fixation is mandatory to achieve a safe and early mobilization, because it is important for patients to return to their previous activity level (1,2). Although choice of the implant varies according to the type of TFs, many studies report that unstable pertrochanteric fractures of the femur, i.e. 31-A2 without medial support, and 31-A3, i.e. intertrochanteric fractures, can be treated successfully with intramedullary (IM) implants. IM fixation devices have become increasingly popular due to biomechanical advantages in the treatment of unstable TFs compared with extramedullary fixation (3-5).

TFs are common in the elderly population and its incidence increases twice in every decade after the age of 50 (6). Although increase in the anterior femoral bow by advanced age has been proved in the literature, the proximal femoral nails (PFN) in the market have still straight designs on the sagittal plane (7,8). Non-anatomic shapes of the PFNs sometimes make the surgeries difficult or can cause additional intraoperative fractures around the tip of the nail because they may impinge to the anterior cortex of the femur and increase the stress at this area due to increased femoral bowing (7-10). This problem is more apparent in shorter patients with shorter femurs, especially in the Asian or Caucasian population. We hypothesized that non-anatomical, straight PFNs impinge to anterior femoral cortex and cause anterior tight pain in patients with increased femoral bow due to increased age and osteoporosis.

The primary outcome of this study was to determine the rate of femoral anterior cortical encroachment after stabilization of the proximal femur in a consecutive series of patients using a short straight PFN. Secondary outcome was to discuss whether PFNs need some improvements in their design for the geriatric population.

Methods

This retrospective study was performed according to Declaration of Helsinki. One hundred and eleven patients with the diagnosis of TF (31-A2.1-3 or 31-A3.1-3 according to Arbeitsgemeinschaft für Osteosynthesefragen/Association for the Study of Internal Fixation's classifications) (11), who had been treated using PFN between 2011 and 2015, were included in the study. The data were collected using files of the patients and the digital database of the hospital. Patients with high-energy trauma, a neoplastic reason for the fractures, open fractures, multiple fractures, the American Society of Anesthesiologists score of 5, inability to walk before the injury, degenerative osteoarthritis/arthritis in the injured hip were excluded from the study. The patients who could not be reached or lost to follow up were also excluded.

The mean age of the patients (59 male and 52 female) was 74.4 (65-95) years. The left hip was involved in 72 cases, and the right hip was involved in 39 cases. The etiologies were simple fall from standing position in 106 patients and pedestrian accident in five patients.

Experienced orthopedic trauma surgeons in a university hospital operated all patients in a standard way. The surgeries were performed using fracture table and under the fluoroscopy. After closed or open reduction (if acceptable reduction could not be achieved by closed reduction techniques), the PFN (InterTAN, Smith&Nephew, Memphis, Tennessee, USA) was inserted in all patients. Its proximal lag screws and distal static locking screws were placed with the appropriate sizes. Final positions of the fractured fragments and the implants were checked under the fluoroscopy before the patients left the operating rooms. On the first postoperative day, an antero-posterior (AP) and lateral X-ray was taken and the patients were allowed walking with weight bearing as they could tolerate.

The digital AP and lateral radiographs taken on the day after surgery and at the 6-month follow up were used for the radiographic measurements. The quality of reduction of the fracture (Garden alignment index) was classified as good, acceptable or poor (12). Position of the proximal screws in the femoral head was calculated by measuring the tip-apex distance (TAD), and the neck-shaft angle (NSA) to evaluate loss in reduction during the follow up (13). Clinical evaluations were performed using Harris Hip Score (HHS) and the visual analog scale (VAS) (14). Loss of reduction, implant failure and complications were recorded.

The angle between the anterior longitudinal axis of the nail and central anatomic axis of the femur at the level of the distal tip of the nail was measured digitally on the lateral radiographs to describe the relation between the anterior of the nail and anterior cortex of the femur. This angle was defined as "angle of distal axes (ADA)". We divided the patients into two groups according to their ADA: group 1 included patients with $ADA \leq 4^\circ$ and group 2 included patients with $ADA > 4^\circ$. All of the radiographs were measured by the same orthopedic surgeon.

Statistical Analysis

Group 1 and 2 were compared in terms of HHS and VAS scores with Kruskal-Wallis test. NSAs on the second postoperative day and at the 6-month follow up radiographs were compared using Wilcoxon signed-ranks test. $P < 0.05$ was accepted as the level of significance.

Results

Quality of reduction was good in 32 patients, acceptable in 12 patients and poor in three patients in group 1, and good in 43 patients, acceptable in 15 patients and poor in six patients in group 2. The mean TAD were 18.3 ± 8.25 mm and 19.7 ± 7.41 mm in group 1 and group 2, respectively.

In group 1 and group 2, the mean early postoperative NSAs were $128.8^\circ \pm 4.5^\circ$ and $130.1^\circ \pm 3.7^\circ$ ($p=0.08$) and the mean final NSAs were $126.8^\circ \pm 6.8^\circ$ and $128.7^\circ \pm 4.1^\circ$ ($p=0.078$), respectively. The mean NSAs were similar initially and at final follow up in group 1 and 2.

The mean amount of ADA was found as $4.5^\circ \pm 1.5^\circ$. Forty-seven patients were classified in group 1 (Figure 1a) and 64 patients were

in group 2 (Figure 1b). The mean HHSs were found as 80.6 ± 2.17 (78-84) points in group 1 and 79.37 ± 3.26 (72-86) points in group 2 ($p=0.464$). The mean VAS scores were 2.13 ± 0.62 (1-3) and 5.35 ± 0.78 (4-7) in groups 1 and 2, respectively ($p<0.001$). Although there was no difference between the groups in terms of the mean HHSs, the VAS scores were found to be significantly lower in group 1 than in group 2.

Cut-out of the lag screws were observed in five patients as complication. In three of these patients, the nails were removed and the fractures were re-reduced and fixed with new PFNs.

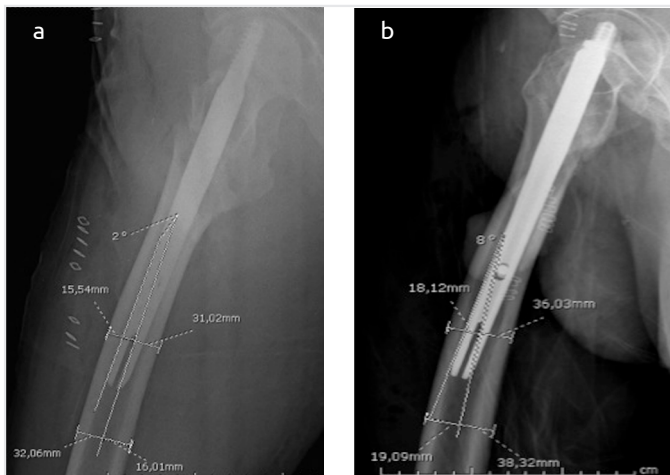


Figure 1. Lateral anatomic axis of the femur at the level of the tip of the nail was determined as the line between the two points which were placed three cm distal and proximal to the tip of the nail and placed at the middle of the anterior and posterior cortices of the femur. Lateral longitudinal axis of the nail was drawn as a line along the anterior border of the nail. Angle of distal axes was the angle between the lateral anatomic axis of the femur and the nail. a) Angle of distal axes=2°, b) angle of distal axes=8°

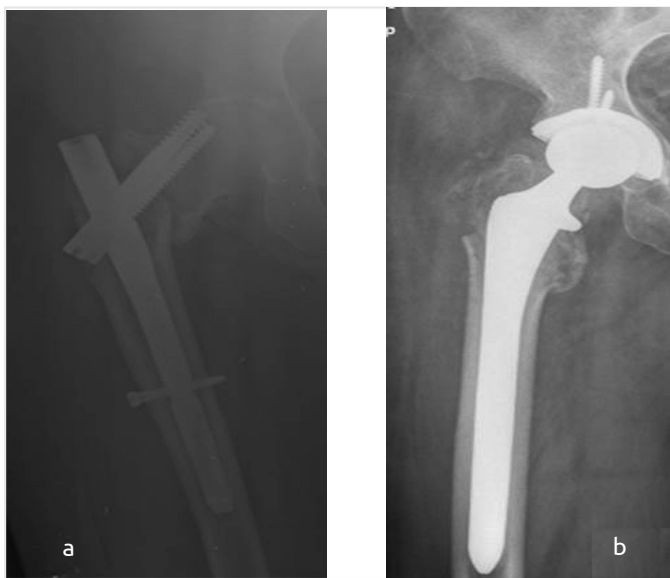


Figure 2. a) Cut-out of the lag screw in a 72-year-old female, b) revision with total hip arthroplasty

However, in two patients, the fractures were treated with total hip arthroplasty (Figures 2a and 2b). During the follow up period, union was achieved in all patients including PFN revisions, except two patients with arthroplasty. Surgical site infection was not observed in any patient. Intraoperative or postoperative fracture of the femur around the distal tip of the nail did not occur in any patient.

Discussion

This retrospective study evaluated 111 patients with TFs who were treated with non-anatomic, straight PFNs. The main goal of the study was to investigate whether straight nails impinged with the anterior femoral cortex due to its anatomic bowing or not. Secondary aim of the study was to evaluate the clinical relevance of this possible impingement. The mean ADA was found as 4.9 ± 1.5 , and it was $>4^\circ$ (grade 3 to 5) in 64 patients (57.6%) which was considered as anterior cortical impingement.

Success of the IM short nails in the treatment of TFs has already been proved. Especially in unstable fractures, they protect proximal femoral anatomy and reduction against the deforming forces (15,16). It is more preferred than the sliding hip screws in the treatment of unstable fractures, including reverse oblique fractures [A3-the AO Foundation and Orthopaedic Trauma Association (AO-OTA)], because the PFN provides higher stability and its use is easier (16,17). Successful results with PFN in large series have been published although it has some complications such as intraoperative fractures, cut-out of the lag screws and varus collapse, nonunion and malunion (3,5,15,16,18). In the treatment of proximal femoral fractures, anterior cortical encroachment of the cephalo-medullary nails have been described before, however, to our knowledge, the relation between anterior cortical impingement and short PFN have not been reported before (19). Similar to the literature, in the current study, successful results with PFN were obtained in 111 patients with unstable TFs (31-A2.1-3 and 31-A3.1-3 AO-OTA) with a total complication rate of 4.5% (11).

In the treatment of TFs with proximal nailing, the most frequent complications are varus collapse of the proximal femur, cut-out of the lag screw, shortening of the femur, nonunion, secondary fracture of the femur or greater trochanter, thigh pain, screw fracture, and Z-effect or reverse Z-effect of nails with two lag screws (20,21). In our series, cut-out of the lag screw was seen in five patients, two of them were treated with arthroplasty and in three patients the nails were revised. Although the amount of varus collapse at the final radiograph compared to initial radiograph, which was about 2° , was statistically significantly different ($p<0.001$) in both groups, it did not have clinical or radiological impact on the results. According to alignment index of Garden, quality of reduction was good in 89% of the patients but poor in 9% of the patients (12). ADA was correlated with thigh pain and VAS scores, which was higher in group 2 ($p<0.001$). This result shows the clinical importance of the anterior impingement of the PFN.

It has been well documented that PFN antirotation (PFNA) (Synthes, Switzerland) may cause femoral fractures or valgus impingement of the lateral cortex, especially in the Asian population (9,22-24). Because of these data in the literature, its proximal diameter, lateral bending angle and lateral surface have been revised and improved, and reproduced as PFNA-II which has been shown to be more appropriate for the Asian population. In the treatment of unstable TFs, biomechanical and clinical studies resulted in superiority of InterTan PFN because of its rotational strength and low rate of malunion (25-28). Anterior cortical impingement or destruction of the femoral nails can lead to potential complications such as thigh pain and disability and serve as a stress riser for future fractures (19,29). Similar problems may occur with straight non-anatomic nails on the sagittal plane (PFNA-II or InterTAN) due to mismatch of the anterior femoral bowing. It has been proved that anterior femoral bowing increases with the increased age and osteoporosis in the elderly; therefore short, straight nails can impinge with the anterior cortex, however the design of the PFNs have not been changed, yet (7-10).

Chang et al. (29) treated 158 patients with unstable TFs using PFNA-II and found encroachment of the distal tip of the nail to the anterior cortex in 55 patients (34.8%). Hwang et al. (9) reported mismatch of PFN/PFNA with the anterior and lateral cortices of the femur in four patients in their series. Radiological studies have also reported mismatch between the femoral nails and increased femoral bowing with advanced age (7,8). Our study showed anterior cortical impingement of the nail in 57.6% of the patients and statistically significantly higher rate of tight pain in this group. In the literature, groin or tight pain after hip nailing is not rare in this group of patients. Inappropriate stress distribution between the femur and the implant is thought to be a reason for tight pain (29-32). Similarly, in our patients, tight pain could be related with increased stress over the anterior cortex of the femur. For this reason, we recommend using shorter or curved nails in order to decrease the stress between the implant and the anterior cortex, which can decrease tight pain and possible fractures around the distal tip of the nail.

Study Limitations

In this study, we had some limitations. First, evaluation of the anterior tight pain could be more objective. Second, stress distribution over the anterior cortex could be evaluated with a biomechanical study to report a measurable data. Third, standardization of the radiological measurements was difficult. ADA was measured on the lateral radiographs, which might change with the rotation of the femur.

Conclusion

Straight, non-anatomic femoral nails impinges anterior cortex of the femur due to increased sagittal bowing of the femur by age and these nails are not appropriate for the shorter people, especially in the Caucasian population. New design proximal femoral nails with anatomic bow can solve these problems.

Ethics

Ethics Committee Approval: Retrospective study.

Informed Consent: Retrospective study.

Peer-review: Externally peer-reviewed.

Authorship Contributions

Surgical and Medical Practices: F.Y., N.M.E., D.K., Concept: F.Y., N.M.E., Y.G., T.E., Design: F.Y., N.M.E., Y.G., Data Collection or Processing: T.E., D.K., Analysis or Interpretation: F.Y., N.M.E., Y.G., Literature Search: F.Y., N.M.E., D.K., T.E., Writing: F.Y., N.M.E., Y.G.

Conflict of Interest: No conflict of interest was declared by the authors.

Financial Disclosure: The authors declared that this study received no financial support.

References

- David A, von der Heyde D, Pommer A. Therapeutic possibilities in trochanteric fractures. Safe--fast--stable. *Orthopade* 2000;29:294-301.
- Efstathopoulos N, Nikolaou VS, Xypnitos FN, Korres D, Lazaretos I, Panousis K, et al. Investigation on the distal screw of a trochanteric intramedullary implant (Fi-nail) using a simplified finite element model. *Injury* 2010;41:259-65.
- Loubignac F, Chabas JF. A newly designed locked intramedullary nail for trochanteric hip fractures fixation: results of the first 100 Trochanteric implantations. *Orthop Traumatol Surg Res* 2009;95:139-44.
- Schipper IB, Marti RK, van der Werken C. Unstable trochanteric femoral fractures: extramedullary or intramedullary fixation. Review of literature. *Injury* 2004;35:142-51.
- Suckel A, Helwig P, Schirmer A, Garbrecht M, Mocke U. [Complication rate in the treatment of inter- and subtrochanteric femur fractures with two intramedullary osteosyntheses. Comparison of a conventional nailing system and a rotation stable fixation of the head-neck-fragment, gammanail and glidingnail]. *Zentralbl Chir* 2003;128:212-7.
- Walter LC, Lui LY, Eng C, Covinsky KE. Risk of hip fracture in disabled community-living older adults. *J Am Geriatr Soc* 2003;51:50-5.
- Harma A, Germen B, Karakas HM, Elmali N, Inan M. The comparison of femoral curves and curves of contemporary intramedullary nails. *Surg Radiol Anat* 2005;27:502-6.
- Karakas HM, Harma A. Femoral shaft bowing with age: a digital radiological study of Anatolian Caucasian adults. *Diagn Interv Radiol* 2008;14:29-32.
- Hwang JH, Oh JK, Han SH, Shon WY, Oh CW. Mismatch between PFNa and medullary canal causing difficulty in nailing of the pertrochanteric fractures. *Arch Orthop Trauma Surg* 2008;128:1443-6.
- Pu JS, Liu L, Wang GL, Fang Y, Yang TF. Results of the proximal femoral nail anti-rotation (PFNA) in elderly Chinese patients. *Int Orthop* 2009;33:1441-4.

11. Marsh JL, Slong TF, Agel J, Broderick JS, Creevey W, DeCoster TA, et al. Fracture and dislocation classification compendium - 2007: Orthopaedic Trauma Association classification, database and outcomes committee. *J Orthop Trauma* 2007;21(Suppl 10):S1-133.
12. Garden RS. Low-angle fixation in fractures of the femoral neck. *Journal of Bone and Joint Surgery (B)* 1961;43:447-63.
13. Baumgaertner MR, Curtin SL, Lindskog DM, Keggi JM. The value of the tip-apex distance in predicting failure of fixation of peritrochanteric fractures of the hip. *J Bone Joint Surg Am* 1995;77:1058-64.
14. Harris WH. Traumatic arthritis of the hip after dislocation and acetabular fractures: treatment by mold arthroplasty. An end-result study using a new method of result evaluation. *J Bone Joint Surg Am* 1969;51:737-55.
15. Norris R, Bhattacharjee D, Parker MJ. Occurrence of secondary fracture around intramedullary nails used for trochanteric hip fractures: a systematic review of 13,568 patients. *Injury* 2012;43:706-11.
16. Niu E, Yang A, Harris AH, Bishop J. Which Fixation Device is Preferred for Surgical Treatment of Intertrochanteric Hip Fractures in the United States? A Survey of Orthopaedic Surgeons. *Clin Orthop Relat Res* 2015;473:3647-55.
17. Pajarinen J, Lindahl J, Savolainen V, Michelsson O, Hirvensalo E. Femoral shaft medialisation and neck-shaft angle in unstable peritrochanteric femoral fractures. *Int Orthop* 2004;28:347-53.
18. Schipper IB, Steyerberg EW, Castelein RM, van der Heijden FH, den Hoed PT, Kerver AJ, et al. Treatment of unstable trochanteric fractures. Randomised comparison of the gamma nail and the proximal femoral nail. *J Bone Joint Surg Br* 2004;86:86-94.
19. Egol KA, Chang EY, Cvitkovic J, Kummer FJ, Koval KJ. Mismatch of current intramedullary nails with the anterior bow of the femur. *J Orthop Trauma* 2004;18:410-5.
20. Lenich A, Vester H, Nerlich M, Mayr E, Stockle U, Fuchtmeyer B. Clinical comparison of the second and third generation of intramedullary devices for trochanteric fractures of the hip--Blade vs screw. *Injury* 2010;41:1292-6.
21. Uzun M, Erturur E, Ozturk I, Akman S, Seckin F, Ozcelik IB. [Long-term radiographic complications following treatment of unstable intertrochanteric femoral fractures with the proximal femoral nail and effects on functional results]. *Acta Orthop Traumatol Turc* 2009;43:457-63.
22. Zhang S, Zhang K, Wang Y, Feng W, Wang B, Yu B. Using three-dimensional computational modeling to compare the geometrical fitness of two kinds of proximal femoral intramedullary nail for Chinese femur. *ScientificWorld Journal* 2013;2013:978485.
23. Simmermacher RK, Ljungqvist J, Bail H, Hockertz T, Vohteloo AJ, Ochs U, et al. The new proximal femoral nail antirotation (PFNA) in daily practice: results of a multicentre clinical study. *Injury* 2008;39:932-9.
24. Lv C, Fang Y, Liu L, Wang G, Yang T, Zhang H, et al. The new proximal femoral nail antirotation-Asia: early results. *Orthopedics* 2011;34:351.
25. Ruecker AH, Rupperecht M, Gruber M, Gebauer M, Barvencik F, Briem D, et al. The treatment of intertrochanteric fractures: results using an intramedullary nail with integrated cephalocervical screws and linear compression. *J Orthop Trauma* 2009;23:22-30.
26. Rupperecht M, Grossterlinden L, Ruecker AH, de Oliveira AN, Sellenschloh K, Nuchtern J, et al. A comparative biomechanical analysis of fixation devices for unstable femoral neck fractures: the Intertan versus cannulated screws or a dynamic hip screw. *J Trauma* 2011;71:625-34.
27. Utrilla AL, Reig JS, Munoz FM, Tufanisco CB. Trochanteric gamma nail and compression hip screw for trochanteric fractures: a randomized, prospective, comparative study in 210 elderly patients with a new design of the gamma nail. *J Orthop Trauma* 2005;19:229-33.
28. Zhang S, Zhang K, Jia Y, Yu B, Feng W. InterTan nail versus Proximal Femoral Nail Antirotation-Asia in the treatment of unstable trochanteric fractures. *Orthopedics* 2013;36:e288-94.
29. Chang SM, Song DL, Ma Z, Tao YL, Chen WL, Zhang LZ, et al. Mismatch of the short straight cephalomedullary nail (PFNA-II) with the anterior bow of the Femur in an Asian population. *J Orthop Trauma* 2014;28:17-22.
30. Yaozeng X, Dechun G, Huilin Y, Guangming Z, Xianbin W. Comparative study of trochanteric fracture treated with the proximal femoral nail anti-rotation and the third generation of gamma nail. *Injury* 2010;41:1234-8.
31. Garg B, Marimuthu K, Kumar V, Malhotra R, Kotwal PP. Outcome of short proximal femoral nail antirotation and dynamic hip screw for fixation of unstable trochanteric fractures. A randomised prospective comparative trial. *Hip Int* 2011;21:531-6.
32. McConnell T, Tornetta P, Benson E, Manuel J. Gluteus medius tendon injury during reaming for gamma nail insertion. *Clin Orthop Relat Res* 2003;199-202.