

**DOI: 10.14235/bs.2018.2211**

**Manuscript Type:** Case Report

**Turkish Title:** Trakeaya Dıştan Bası Yaparak Ağır Nefes Darlığına Yol Açan Klavikula Enostozisi

**Turkish Running Head:** Nefes darlığına yol açan enostozis

**Title:** Enostosis on Clavicle Causing Severe Dyspnea by Compressing The Trachea Externally

**Running Head:** Enostosis Causing Severe Dyspnea

**Authors:** Osman Cemil AKDEMİR<sup>1</sup> Abdülaziz KÖK<sup>1</sup> Sedat ZİYADE<sup>1</sup> Nuh Mehmet ELMADAĞ<sup>2</sup> Erkan ÇAKIR<sup>3</sup> Mehmet BİLGİN<sup>4</sup> Ömer SOYSAL<sup>1</sup> Nur BÜYÜKPINARBAŞLI<sup>5</sup>

**Institutions:** <sup>1</sup>Department of Thoracic Surgery, Bezmialem Vakif University School of Medicine, İstanbul, Turkey

<sup>2</sup>Department of Orthopedy, Bezmialem Vakif University School of Medicine, İstanbul, Turkey

<sup>3</sup>Department of Child Thoracic Surgery, Bezmialem Vakif University School of Medicine, İstanbul, Turkey

<sup>4</sup>Department of Child Radiology, Bezmialem Vakif University School of Medicine, İstanbul, Turkey

<sup>5</sup> Department of Child Pathology, Bezmialem Vakif University School of Medicine, İstanbul,

**Address for Correspondence:** Sedat ZİYADE, Department of Thoracic Surgery, Bezmialem Vakif University School of Medicine, İstanbul, Turkey

**E-mail:** [sedatziyade@gmail.com](mailto:sedatziyade@gmail.com)

**Cite this article as:** Akdemir OC, Kök A, Ziyade S, Elmadağ NM, Çakır E, Bilgin M et al. Enostosis on Clavicle Causing Severe Dyspnea by Compressing The Trachea Externally. Bezmialem Science 2018.

DOI: 10.14235/bs.2018.2211

This article has been accepted for publication and undergone full peer review but has not been through the copyediting, typesetting, pagination and proofreading process, which may lead to differences between this version and the Version of Record. Please cite this article as: Akdemir OC, Kök A, Ziyade S, Elmadağ NM, Çakır E, Bilgin M et al. Enostosis on Clavicle Causing Severe Dyspnea by Compressing The Trachea Externally Bezmialem Science 2018. DOI: 10.14235/bs.2018.2211

©Copyright 2018 by Bezmialem Vakif University - Available online at [www.bezmialemscience.org](http://www.bezmialemscience.org)

## ABSTRACT

Clavicle is the bone that forms anterior border of shoulder arch. It lies on anterosuperior of thorax with first rib. Clavicle is very near to major vascular structures, brachial plexus, esophagus and trachea at thoracic inlet. Because of this, clavicular lesions fractures and sternoclavicular dislocations -especially posterior dislocations- may cause symptoms due to compressing symptoms due to these structures. In this article we present a case with enostosis of clavicle causing respiratory failure by compressing on trachea.

**Keywords:** Clavicle, enostosis, respiratory failure

## Öz

Klavikula omuz kemerinin ön sınırını yapan kemiktir. Birinci kot ile birlikte toraksın anterosüperiorunda bulunur. Klavikula, torasik inlette, major vasküler yapılara, pleksus brakiyalise, özofagus ve trakeaya çok yakındır. Bu nedenle, klavikula lezyonları, fraktürleri ve sternoklaviküler çıkıklar ve özellikle posterior çıkıklar bu oluşumlara bası semptomları oluşturabilir. Bu yazıda, trakeaya bası ile solunum yetmezliği yapan bir klaviküler enostozisli olgu sunduk.

**Anahtar Kelimeler:** Clavicle, enostosis, respiratory failure

This article has been accepted for publication and undergone full peer review but has not been through the copyediting, typesetting, pagination and proofreading process, which may lead to differences between this version and the Version of Record. Please cite this article as: Akdemir OC, Kök A, Ziyade S, Elmadağ NM, Çakır E, Bilgin M et al. Enostosis on Clavicle Causing Severe Dyspnea by Compressing The Trachea Externally Bezmialem Science 2018. DOI: 10.14235/bs.2018.2211

## Introduction

Clavicle is the bone that forms anterior border of shoulder arch. It lies on anterosuperior of thorax with first rib (1). At the upper thoracic inlet, around sternoclavicular joints area, both of clavicle are anatomically near with subclavian arteries and veins, both brachial plexuses esophagus and trachea, both carotid arteries and jugular veins. Because of nearness to major vascular structures, brachial plexus, esophagus and trachea at thoracic inlet clavicle lesions, fractures and sternoclavicular dislocations -especially posterior dislocations- causes symptoms due to these structures being affected.

## Case

A six year old girl referred pediatric pulmonology outpatient clinic complaining of irritative cough and dyspnea that continues for a long time in spite of medical treatment. At the history, three months before, there was an hospitalisation event in intensive care unit because of occurrence of respiratory failure after a coughing crisis. At flexible bronchoscopy, there was a pulsatile externally compressing lesion on anterior wall of trachea.(Picture 1).

At thorax CT angiography there was a lesion protrude in to mediastinum. It may be hypertrophy of the bone or osteophyte. At the below of this right subclavian artery was scating and compressing on trachea at the junction of right common carotid artery and right subclavian artery(Picture 2).

Mediastinal vascular structures were normal. On physical examination it was determined that thoracic inlet area is closefitting because of wide interclavicular ligament. It was thought that pulsatile externally compression seemed at flexible bronchoscopy caused by the lesion on clavicle, and operation was decided. Clavicle was reached by an incision started at upper point of sternum through laterally to the medial head of clavicle. Approximately 1 cm long and 4-5 mm thick, hard and tight interclavicular ligament was seemed and excised. Head of right clavicle was explored by periosteum opened(Picture 4-5).

Hypertrophic tissue protruding posteriorly was excised. Mediastinum was controlled by finger dissection as it was relaxed. Procedure was finished after placing a minivac drain to the dissection area. At postoperative CT, compression on mediastinal structures was seemed to be disappeared (Picture

This article has been accepted for publication and undergone full peer review but has not been through the copyediting, typesetting, pagination and proofreading process, which may lead to differences between this version and the Version of Record. Please cite this article as: Akdemir OC, Kök A, Ziyade S, Elmadağ NM, Çakır E, Bilgin M et al. Enostosis on Clavicle Causing Severe Dyspnea by Compressing The Trachea Externally *Bezmialem Science* 2018. DOI: 10.14235/bs.2018.2211

3). The patient was discharged first day. Pathology was reported as enostosis (bone island). The patient is followed postoperative sixth month and she have nor cough neither dyspnea.

## Discussion

Posteriorly dislocations may cause some symptoms due to compression of head of clavicle to contiguous structures and injuries or lacerations may occur due to direct effect or trauma. In the literature there are cases of injury or laceration of innominate vein, innominate artery, esophagus, trachea, brachial plexus, and even vena cava or compression to vena cava because of posteriorly dislocation and cases diagnosed by compressions symptoms of tumours on head of clavicle (2-9), We did not run across a case reported by enostosis. Pathologies on this area may have crucial risks. Until now, mortality because of posteriorly dislocation of clavicle related injury was reported on five cases (10). In this article we aimed to emphasize the importance of pathologies on the head of clavicle on cases with external compression to trachea causing respiratory failure,

Bone Island (enositozis) is a focus of compact bone located in cancellous bone. This is a benign entity that is rarely symptomatic and that is usually found incidentally with radiological studies. Symptoms are pain and protuberance due to enlargement of the lesion. In our case on physical examination there were no protuberance but it was determined that thoracic inlet area is closefitting because of wide interclavicular ligament. In radiological examination there was a lesion on the head of right clavicle protrude to mediastinum may be hyperthrophy or osteophyte. Under this lesion, right subclavian artery was bending to posteriorly and compressing to trachea on the junction with right carotid artery.

Tracheal stenosis caused by externally compression may cause recurrent pulmonary infections, symptoms like wheezing, chronic cough and even respiratory failure. Diseases with vascular abnormalities, aneurysms, mediastinal masses, lymphadenopathies may cause tracheal stenosis. Lesions on the head of clavicle are extremely rare in these causes. In differential diagnosis of this clinical situations, lesions compressing to trachea externally, and foreign body aspirations must be considered. For diagnosis flexible bronchoscopy and thorax CT with intravenous contrast must be used. So that localisation and severity of stenosis, and lesion causing stenosis may be determined and treatment may be planned.

This article has been accepted for publication and undergone full peer review but has not been through the copyediting, typesetting, pagination and proofreading process, which may lead to differences between this version and the Version of Record. Please cite this article as: Akdemir OC, Kök A, Ziyade S, Elmadağ NM, Çakır E, Bilgin M et al. Enostosis on Clavicle Causing Severe Dyspnea by Compressing The Trachea Externally *Bezmialem Science* 2018. DOI: 10.14235/bs.2018.2211

## Conclusion

On cases with external compression to trachea causing respiratory failure, pathologies on the head of clavicle must be minded. Bone island is one of them. In treatment, removing the compression on vascular structures in case the trachea by excision of the head of clavicle partially may be performed and result is satisfactory in terms of symptoms.

## References

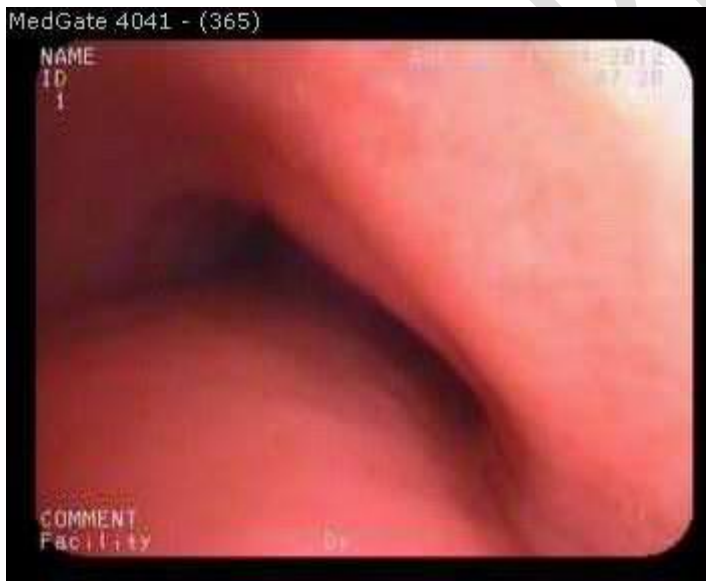- 1-Gray, Henry. Anatomy of the Human Body. Philadelphia: Lea&Febriger, 1918; Bartelby.com, 2000. [www.bartelby.com/107/](http://www.bartelby.com/107/).
- 2- Peter Carbone, Matthew Rose, Joseph A. O'DanielWilliam C. DoukasRobert V. O'Toole, and Romney C. Andersen,. Posterior Remodeling of Medial Clavicle Causing Superior Vena Cava Impingement. [www.amjorthopedics.com](http://www.amjorthopedics.com): June 2011; **297**
- 3- M. Fenig, R. Lowman, B.P. Thompson, P.H. Shayne.Fatal posterior sternoclavicular joint dislocation due to occult trauma. *Am J Emerg Med*, 28 (2010), pp. 5–8
- 4- Mollano AV, Hagy ML, Jones KB, Buckwalter JA. Unusual osteochondroma of the medial part of the clavicle causing subclavian vein thrombosis and brachial plexopathy. A case report. *J Bone Joint Surg Am*. 2004;86(12):2747-2750.
- 5- D.M. Gangahar, T. Flogaites. Retrosternal dislocation of the clavicle producing thoracic outlet syndrome. *J Trauma*, 18 (1978), p. 369
- 6- E. Nakayama, T. Tanaka, T. Noguchi, J. Yasuda, Y. Terada. Tracheal stenosis caused by retrosternal dislocation of the right clavicle. *Ann Thorac Surg*, 83 (2007), pp. 685–687  
<http://dx.doi.org/10.1016/j.athoracsur.2006.06.022>
- 7- K. Ono, H. Inagawa, K. Kiyota, T. Terada, S. Suzuki, K. Maekawa. Posterior dislocation of the sternoclavicular joint with obstruction of the innominate vein: Case report. *J Trauma*, 44 (1998), pp. 381–383

This article has been accepted for publication and undergone full peer review but has not been through the copyediting, typesetting, pagination and proofreading process, which may lead to differences between this version and the Version of Record. Please cite this article as: Akdemir OC, Kök A, Ziyade S, Elmadağ NM, Çakır E, Bilgin M et al. Enostosis on Clavicle Causing Severe Dyspnea by Compressing The Trachea Externally *Bezmialem Science* 2018. DOI: 10.14235/bs.2018.2211

8- J.A. Sykes, C. Ezetendu, A. Sivitz, J. Lee Jr., H. Desai, K. Norton et al. Posterior dislocation of sternoclavicular joint encroaching on ipsilateral vessels in 2 pediatric patients. *Pediatr Emer Care*, 27 (2011), pp. 327–330 <http://dx.doi.org/10.1097/PEC.0b013e318217b58f>

9- M.J. Wasylenko, E.F. Busse. Posterior dislocation of the clavicle causing fatal tracheoesophageal fistula. *Can J Surg*, 24 (1981), pp. 626–627

10- Garg S, Alshameeri ZA, Wallace WA. Posterior sternoclavicular joint dislocation in a child: a case report with review of literature. *J Shoulder Elbow Surg*. 2012 Mar;21(3):e11-6. Epub 2011 Oct 17.



**Figure 1**

This article has been accepted for publication and undergone full peer review but has not been through the copyediting, typesetting, pagination and proofreading process, which may lead to differences between this version and the Version of Record. Please cite this article as: Akdemir OC, Kök A, Ziyade S, Elmadağ NM, Çakır E, Bilgin M et al. Enostosis on Clavicle Causing Severe Dyspnea by Compressing The Trachea Externally *Bezmialem Science* 2018. DOI: 10.14235/bs.2018.2211

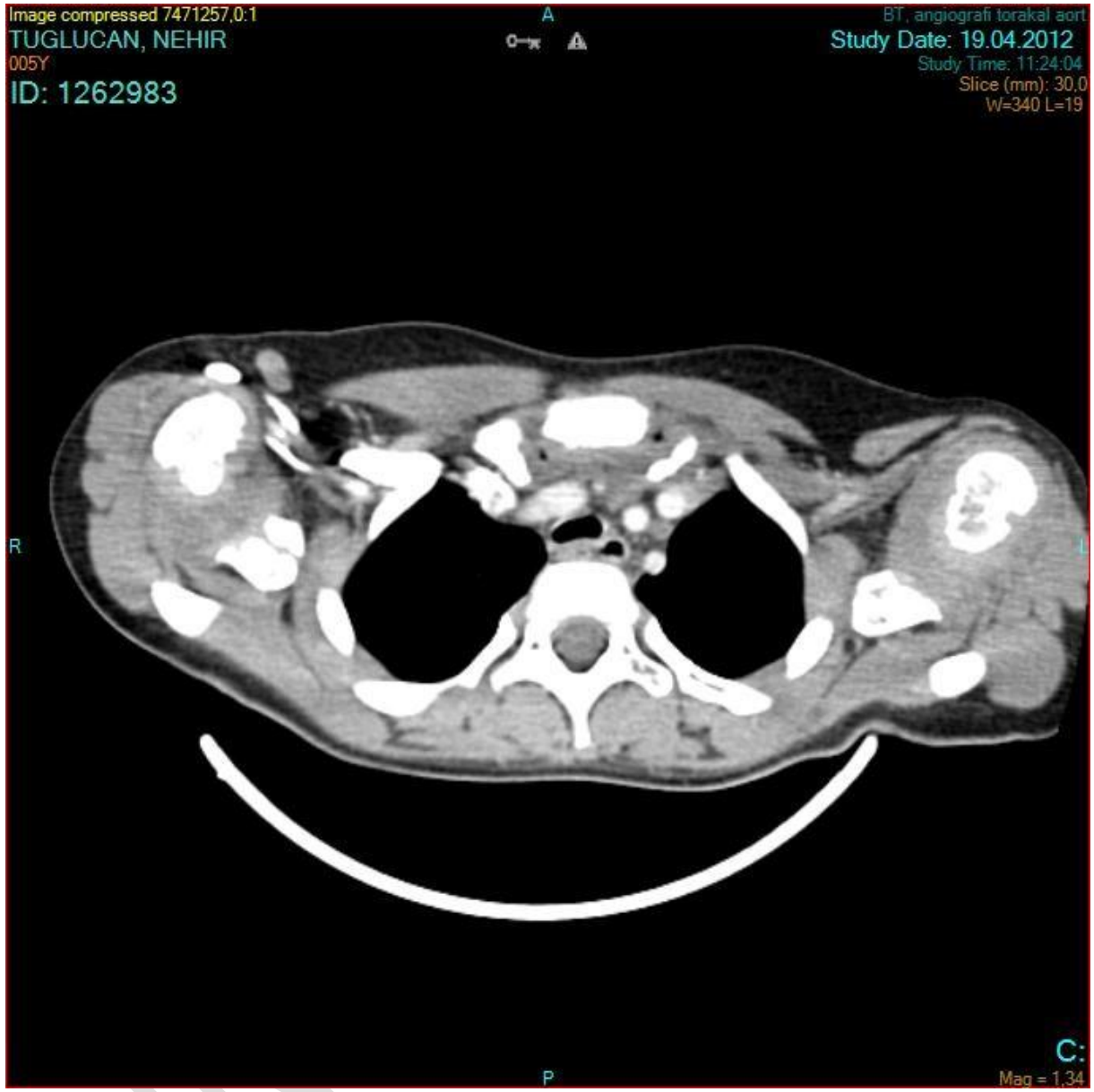
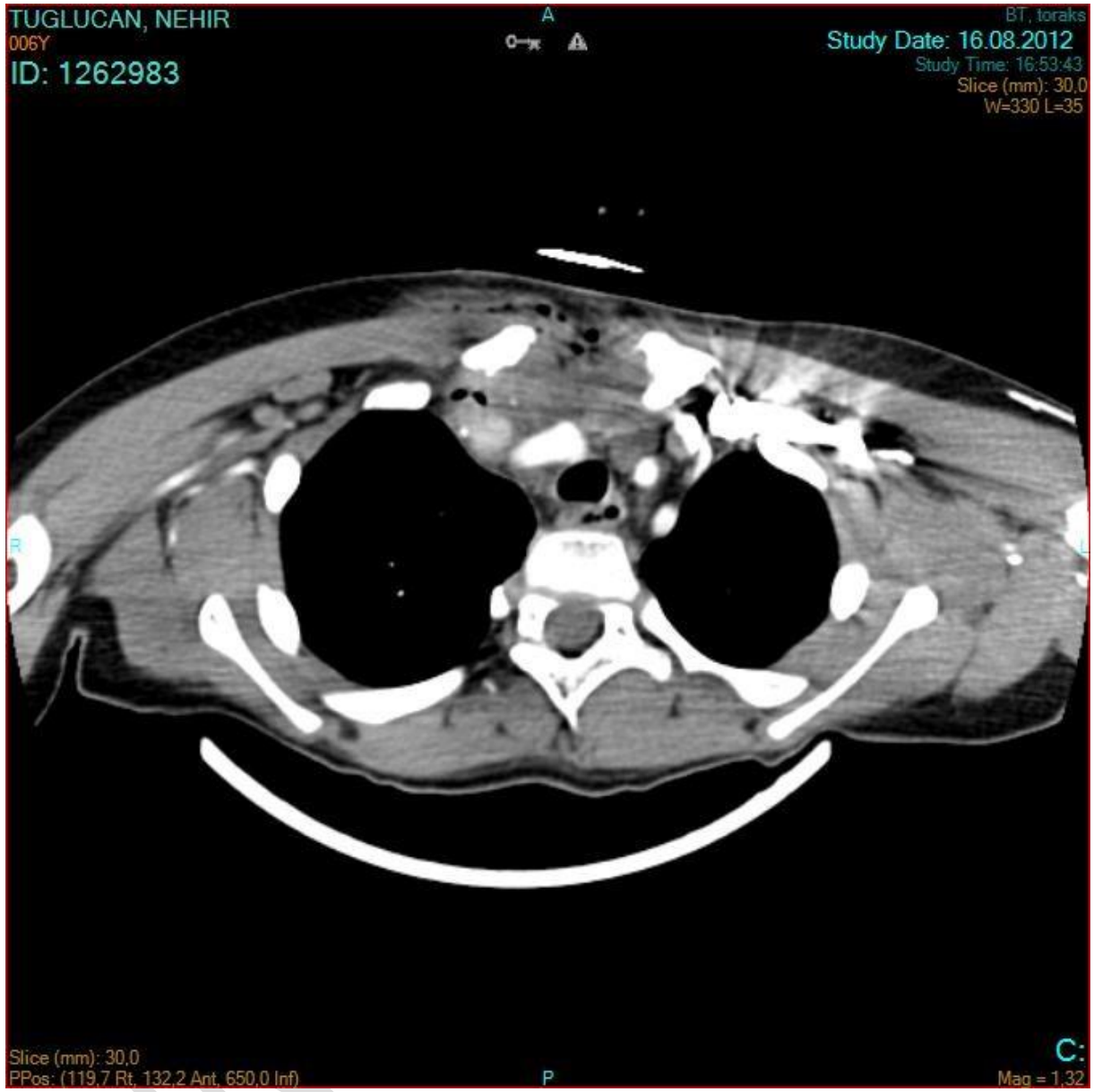


Figure 2

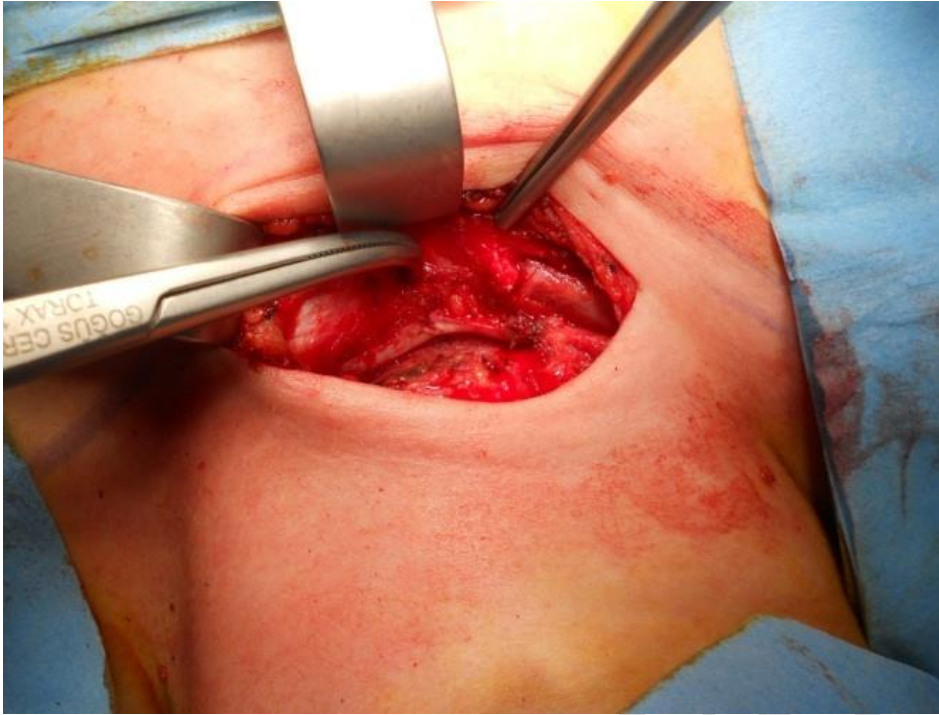
This article has been accepted for publication and undergone full peer review but has not been through the copyediting, typesetting, pagination and proofreading process, which may lead to differences between this version and the Version of Record. Please cite this article as: Akdemir OC, Kök A, Ziyade S, Elmadağ NM, Çakır E, Bilgin M et al. Enostosis on Clavicle Causing Severe Dyspnea by Compressing The Trachea Externally Bezmialem Science 2018. DOI: 10.14235/bs.2018.2211



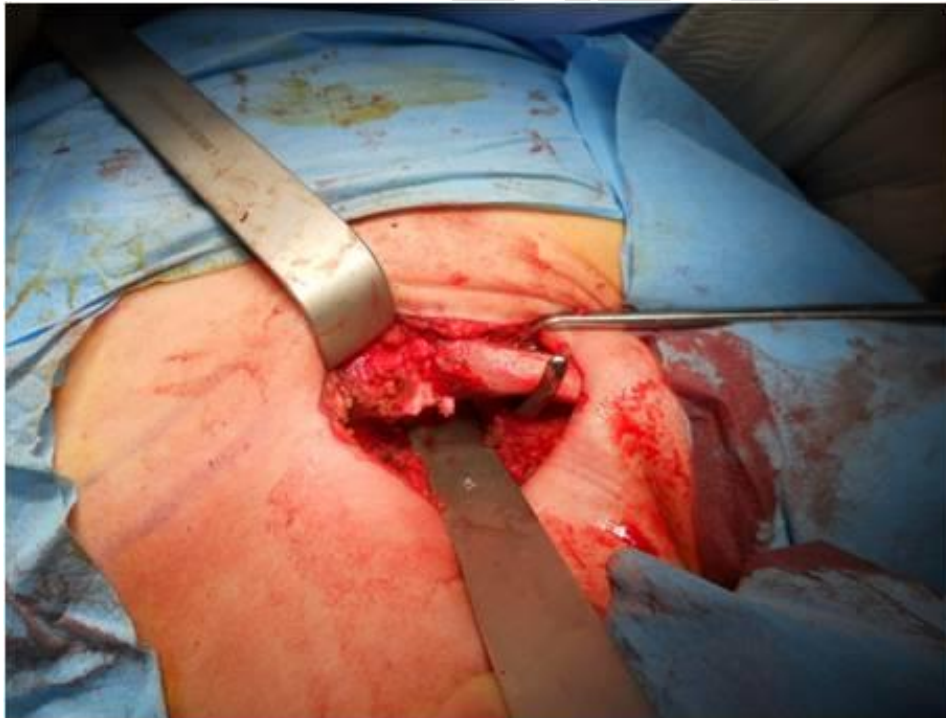**Figure 3**

This article has been accepted for publication and undergone full peer review but has not been through the copyediting, typesetting, pagination and proofreading process, which may lead to differences between this version and the Version of Record. Please cite this article as: Akdemir OC, Kk A, Ziyade S, Elmadađ NM, akır E, Bilgin M et al. Enostosis on Clavicle Causing Severe Dyspnea by Compressing The Trachea Externally Bezmialem Science 2018. DOI: 10.14235/bs.2018.2211





**Figure 4**



**Figure 5**

This article has been accepted for publication and undergone full peer review but has not been through the copyediting, typesetting, pagination and proofreading process, which may lead to differences between this version and the Version of Record. Please cite this article as: Akdemir OC, Kök A, Ziyade S, Elmadağ NM, Çakır E, Bilgin M et al. Enostosis on Clavicle Causing Severe Dyspnea by Compressing The Trachea Externally Bezmialem Science 2018. DOI: 10.14235/bs.2018.2211