

# A Rare Confusing Nevus Variant: Meyerson Nevus

## Karışıklara Yol Açabilecek Nadir Bir Nevüs Varyantı: Meyerson Nevüs

Pelin YILDIZ<sup>1</sup> , Özlem Su KÜÇÜK<sup>2</sup> , Zeynep TOSUNER<sup>1</sup> , Belfin Nur ARICI<sup>3</sup> , Didem DİZMAN<sup>2</sup> ,  
Uğur DEVECİ<sup>4</sup>, Cuyan DEMİRKESEN<sup>5</sup> 

<sup>1</sup>Department of Pathology, Bezmialem Vakıf University School of Medicine, İstanbul, Turkey

<sup>2</sup>Department of Dermatology, Bezmialem Vakıf University School of Medicine, İstanbul, Turkey

<sup>3</sup>Istanbul Community Health Center, İstanbul, Turkey

<sup>4</sup>Department of General Surgery, Maltepe University School of Medicine, İstanbul, Turkey

<sup>5</sup>Department of Pathology, Acıbadem University School of Medicine, İstanbul, Turkey

### ABSTRACT

Meyerson nevus is a rare benign entity described by Meyerson et al in 1971 as a melanocytic nevus surrounded by inflammatory, eczematous eruption that resolves spontaneously or by topical steroid therapy (fluticasone propionate, Abdi İbrahim İlaç San. ve Tic. A.Ş., İstanbul), but the nevus persists. This entity is not well known and there is limited information in the literature. Since the lesion may develop suspicion for malignancy, it is important to keep this entity in mind. In this article we present three Meyerson nevi, two of which belong to one patient.

**Keywords:** Meyerson, nevus, rare, variant

### ÖZ

Meyerson nevüs, ilk defa 1971 yılında Meyerson ve arkadaşları tarafından tanımlanan, üzerinde ve/veya çevresinde ona eşlik eden ekzematöz reaksiyonla karakterize bir melanositik nevüs çeşididir. Erupsiyon kendiliğinden veya topikal tedavilerle giderilken, nevüs devamlılık gösterir. İyi bilinmeyen bu antiteyle ilgili, klasik kitaplar ve yayınlarda sınırlı bilgi bulunmaktadır. Lezyon malignite açısından şüphe uyandırabileceğinden, akılda tutulması önemlidir. Bu makalede ikisi aynı hastada olmak üzere üç Meyerson nevüs olgusu sunulacaktır.

**Anahtar Kelimeler:** Meyerson, nevüs, nadir, varyant

### Introduction

Meyerson nevus is described as a melanocytic nevus surrounded by inflammatory, eczematous eruption, and was first described by Meyerson in 1971 (1). In this article, two patients with melanocytic nevi surrounded by eczema, characterized by histologic features of parakeratosis, spongiosis, acanthosis in the epidermis and perivascular lymphocytic infiltrate within the dermis, were described. Topical steroid therapy succeeded to resolve the lesion leaving a slight hypopigmentation around the unchanged nevi (2, 3).

Since then, not only pigmented (junctional nevi, Sutton nevi, atypical nevi, and congenital nevi) but also non-melanocytic lesions (basal cell carcinomas, spinocellular carcinomas, seborrheic keratosis, keloids, dermatofibromas, and insect bites) were documented with the findings of eczematization (3).

This entity of eczematization of the centrally located nevi/lesion is called as Meyerson phenomenon (halo dermatitis) (4-6).

Here we report three cases of Meyerson nevus, two of which were seen in the same person.

**Cite this article as:** Yıldız P, Küçük ÖS, Tosuner Z, Arıcı BN, Dizman D, Devci U. A Rare Confusing Nevus Variant: Meyerson Nevus. *Bezmialem Science* 2018; 6: 80-2.

This study was presented at the 24<sup>th</sup> National Pathology Congress (2014 Trabzon, Turkey)

Bu çalışma, 24. Ulusal Patoloji Kongresi'nde (2014, Trabzon Türkiye) sunulmuştur.

**Address for Correspondence/Yazışma Adresi:** Pelin YILDIZ, Bezmialem Vakıf Üniversitesi Tıp Fakültesi, Patoloji Anabilim Dalı, İstanbul, Türkiye E-mail: drpelinyildiz@gmail.com

©Telif Hakkı 2018 Bezmialem Vakıf Üniversitesi - Makale metnine [www.bezmialemscience.org](http://www.bezmialemscience.org) web sayfasından ulaşılabilir.  
©Copyright 2018 by Bezmialem Vakıf University - Available online at [www.bezmialemscience.org](http://www.bezmialemscience.org)

Received / Geliş Tarihi : 10.07.2016  
Accepted / Kabul Tarihi: 12.11.2016

## Case Reports

### Case 1

A 23-year-old woman with atopic dermatitis presented with a 0.4 cm pigmented, keratotic, itchy lesion on her groin. Two months later she attended to dermatology clinic with another excoriated lesion on her chest. In dermoscopic examination, (Fotofinder systems, Bayern, Germany) both lesions had irregular borders with a negative pigmented network and some blue-gray areas reminiscent of regression on an erythematous background. Pigmented globules were detected at the periphery (Figure 1). The lesions were excised with a prediagnosis of dysplastic nevi. Histopathological examination revealed lentiginous hyperplasia, containing some small melanocytic nests at the dermoepidermal junction. Some nests at the tips of rete ridges had a bridging tendency. Due to excoriation, nuclear fragments and plasma exudation were seen on the surface. Remarkable feature was diffuse lymphohistiocytic infiltrate in the upper dermis (Figure 2). Additionally, prominent spongiosis (Figure 3) and few eosinophils were noted within the epidermis.

Both lesions were diagnosed as eczematous lentiginous nevus with Meyerson phenomenon (Meyerson nevus).

### Case 2

The second patient was a 51-year-old man, presenting with a 0.7 cm pigmented lesion on his lumbar region. Since the lesion was suspicious for malignancy, it was excised. The patient had similar microscopic features with the former patient such as prominent spongiosis, eosinophilic spongiosis in the epidermis, and perivascular lymphocytic infiltration. Furthermore melanocytic nests were detected in the dermis.

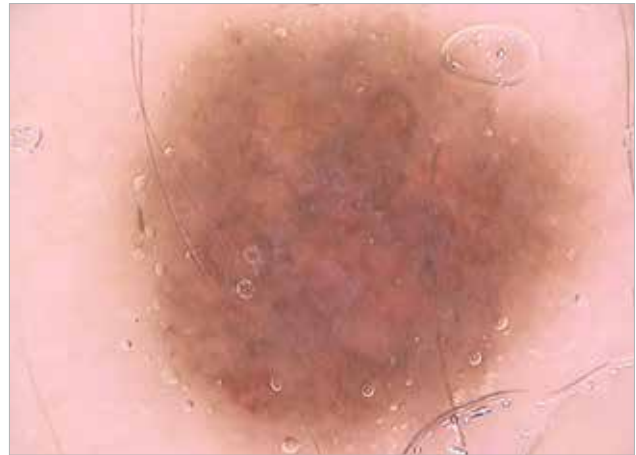This lesion was reported as eczematous compound dysplastic nevus (Meyerson nevus).

## Discussion

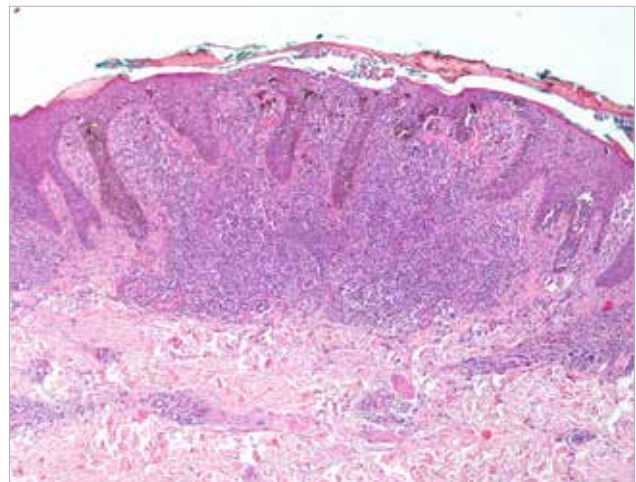
Meyerson nevus is a rare entity, described as a symmetrical erythema and scale over or around centrally localized melanocytic nevus due to eczematization. Occasional cases with atopic dermatitis have been reported (4). Our first patient had some features of atopy such as eczematous dermatitis, xerosis, and pruritus, from her childhood.

Broadly, immediate change of size and loss of symmetry could raise the suspicion for malignancy. Under these circumstances, dermoscopic appearance of the Meyerson nevus could be challenging. Also, on microscopic evaluation, diffuse inflammatory reaction could be alarming. Although coexistence with malignancy was described (1), even benign nevus could raise suspicion for malignancy as in our second patient. It is important to separate this benign condition from malignant tumors with inflammation.

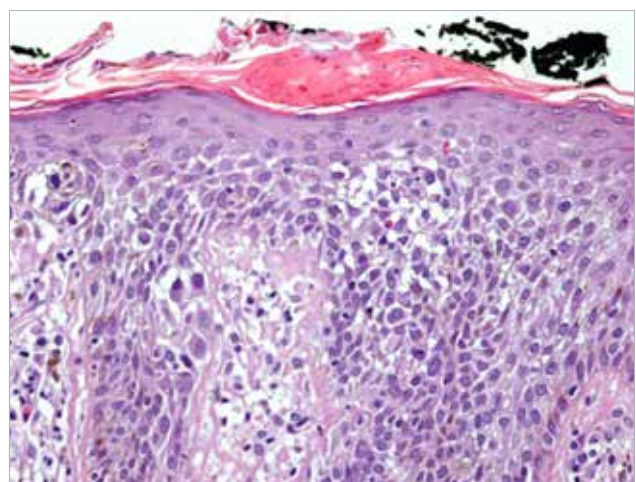
The findings of eczematization resolve in time and need no therapy, but underlying lesion persists. Topical steroids and surgical excision are the choices for the therapy (4, 7).



**Figure 1. (Patient 1: first lesion) Negative pigment network and some blue-gray areas in favor of regression on erythematous background, some peripheral pigmented globules**



**Figure 2. (Patient 1: first lesion) Marked excoriation and eczematization, increased pigmentation, diffuse lymphohistiocytic infiltrate in the upper dermis (HEX40)**



**Figure 3. (Patient 1: first lesion) Spongiosis, eosinophilic spongiosis, and melanocytic nests in the epidermis (HEX200)**

The nevi were resected with free margins. No complaint or recurrence was stated after the excision.

Meyerson postulated pityriasis rosea as the cause of eruption, but it is unclear. Some other triggering factors were suggested as ultraviolet radiation, chemotherapy, alpha-2B interferon therapy for HCV and Behçet's disease (2, 6).

Halo (Sutton) nevus should be considered in the differential diagnosis. It is usually a pigmented lesion, sometimes a neuroid nevus, a blue nevus, a neurofibroma, or a primary or secondary malignant melanoma, surrounded by a halo of depigmented zone. Depigmented zone had no clinical signs of inflammation. In the original descriptions, Meyerson nevus had neither regression nor depigmentation of the central lesion (8-10).

## Conclusion

Meyerson nevus is a rare benign entity. It is not well known and there is limited information in the literature. Since, the lesion might develop suspicion for malignancy, like in our patients, it is important to keep this entity in mind. More patients and long follow up could help to clarify the pathogenesis of Meyerson nevus and association between the other lesions.

**Informed Consent:** Written informed, consent was obtained from patient who participated in this case.

**Peer-review:** Externally peer-reviewed.

**Author Contributions:** Concept - P.Y., Ö.S.K., C.D.; Design - P.Y., Z.T., D.D.; Supervision - P.Y., Ö.S.K., C.D.; Resource - B.N.A., U.D., P.Y.; Materials - Ö.S.K., D.D., P.Y.; Data Collection and/or Processing - P.Y., D.D., B.N.A., U.D.; Analysis and/or Interpretation - P.Y., Z.T., C.D.; Literature Search - P.Y., Z.T.; Writing - P.Y., C.D., Ö.S.K., Z.T.; Critical Reviews - C.D., Ö.S.K.

**Conflict of Interest:** No conflict of interest was declared by the authors.

**Financial Disclosure:** The authors declared that this study has received no financial support.

**Hasta Onamı:** Yazılı hasta onamı bu çalışmaya katılan hastadan alınmıştır.

**Hakem Değerlendirmesi:** Dış bağımsız.

**Yazar Katkıları:** Fikir - P.Y., Ö.S.K., C.D.; Tasarım - P.Y., Z.T., D.D.; Denetleme - P.Y., Ö.S.K., C.D.; Kaynaklar - B.N.A., U.D., P.Y.; Malzemeler - Ö.S.K., D.D., P.Y.; Veri Toplanması ve/veya İşlemesi - P.Y., D.D., B.N.A., U.D.; Analiz ve/veya Yorum - P.Y., Z.T., C.D.; Literatür Taraması - P.Y., Z.T.; Yazıyı Yazan - P.Y., C.D., Ö.S.K., Z.T.; Eleştirel İnceleme - C.D., Ö.S.K.

**Çıkar Çatışması:** Yazarlar çıkar çatışması bildirmemişlerdir.

**Finansal Destek:** Yazarlar bu çalışma için finansal destek almadıklarını beyan etmişlerdir.

## References

1. Meyerson LB. A peculiar papulosquamous eruption involving pigmented nevi. *Arch Dermatol* 1971; 103: 510-2. [\[CrossRef\]](#)
2. Fernandez-Flores A. Eponyms, morphology, and pathogenesis of some less mentioned types of melanocytic nevi. *Am J Dermatopathol* 2012; 34: 607-18. [\[CrossRef\]](#)
3. Gabbi TV, Omar ED, Criado PR, Valente NY, Martins JE. Clinical, dermoscopic and histopathological evaluation of the Meyerson nevus: case report. *An Bras Dermatol* 2010; 85: 681-3. [\[CrossRef\]](#)
4. Rolland S, Kokta V, Marcoux D. Meyerson phenomenon in children: observation in five cases of congenital melanocytic nevi. *Pediatr Dermatol* 2009; 26: 292-7. [\[CrossRef\]](#)
5. Simon V, Hartschuh W, Flux K. Meyerson-Phenomenon hides a nevus flammeus. *J Dtsch Dermatol Ges* 2011; 9: 305-7. [\[CrossRef\]](#)
6. Schofield C, Weedon D, Kumar S. Dermatofibroma and halo dermatitis. *Australas J Dermatol* 2012; 53: 145-7. [\[CrossRef\]](#)
7. Schepis C, Siragusa M. The Meyerson phenomenon in a teenager. *Dermatol Online J* 2008; 14: 28.
8. Rodins K, Byrom L, Muir J. Early melanoma with halo eczema (Meyerson's phenomenon). *Australas J Dermatol* 2011; 52: 70-3. [\[CrossRef\]](#)
9. Weedon D, Farnsworth J. Spongiotic changes in melanocytic nevi. *Am J Dermatopathol* 1984; 6(Suppl): 257-9.
10. Kus S, Ince U, Candan I, Gurunluoglu R. Meyerson phenomenon associated with dysplastic compoundnevi. *J Eur Acad Dermatol Venereol* 2006; 20: 350-1. [\[CrossRef\]](#)